

Patient Safety Alert

File Number: 16/17- 07
February 7, 2017

DISCONTINUE USE OF MAGNESIUM SULFATE (EPSOM SALT) ENEMAS

When a patient or resident experiences constipation, an enema is often ordered to ease symptoms and assist in passing stool. The use of Epsom salt/magnesium sulfate enemas (also known as 2-4-6 enemas) are not recommended because of the ability of the colon to absorb elemental magnesium which can contribute to hypermagnesemia in patients.

RECOMMENDATIONS

The Ministry of Health recommends:

- **Regional health authorities and health care organizations discontinue the use of magnesium sulfate/2-4-6 enemas for treatment of constipation in patients and residents.**
- **Safer alternatives include tap water or polyethylene glycol-containing enemas.**

Supporting Documents

1. *Iatrogenic hypermagnesemia following Epsom salt enema.* Prystajecy MR, Parent S, Rehman HU. Journal of Acute Medicine 5 (2015) 80-83

Background of the Critical Incident

An 85 year old patient presented to the emergency department of an acute care facility with a three day history of constipation and abdominal pain. The patient was in end-stage renal failure and was receiving hemodialysis. The results of blood work showed the patient's magnesium level was 0.81mmol/L (within the normal range of 0.70-1.10mmol/L). Abdominal X-rays showed stool in the right side colon and rectum. A 2-4-6 Epsom salt enema (which contained 60mL of Epsom salts and 120mL of glycerin and water) was administered followed by a repeat abdominal X-ray. Following the enema, there was no evacuation of stool.

Approximately 70 minutes post-administration, the patient called out for help and advised staff of feeling weak. Vital signs were taken and the patient was sent to the medical imaging department for the repeat X-ray. Upon arrival in medical imaging, the patient's level of consciousness was noted to be decreased. The patient was moved to a major trauma/resuscitation room and attached to continuous monitoring. Repeat blood work revealed a critically high magnesium level (> 7.8mmol/L, the actual value being higher than the equipment was capable of measuring). Consultations were made to hematology, nephrology, and internal medicine. The patient was admitted to a cardiac monitoring bed for further treatment with a diagnosis of hypermagnesemia.

The patient's level of consciousness improved, the patient received hemodialysis, and magnesium levels normalized over the next several days. The patient continued to experience fatigue, poor appetite, and weakness. Nine days following the incident the patient declined further hemodialysis; comfort measures were given and the patient died two weeks later.

Analysis

A 2-4-6 enema contains 28 g of Epsom salts, or 2.8 g of elemental magnesium (the equivalent of eight times the recommended dietary allowance for magnesium intake for an adult). One enema contains enough magnesium to cause fatal toxicity in a patient.

Hypermagnesemia can be fatal, especially if a delay in diagnosis occurs. Initial symptoms of hypermagnesemia, such as nausea, vomiting, and weakness, are nonspecific and can progress rapidly to respiratory depression, hypotension, cardiac arrest, and death. Hypermagnesemia is most commonly seen in patients with renal insufficiency. However, it can also be seen in individuals with normal renal function if enough magnesium is administered (either orally, intravenously, or rectally) and absorbed. Other risk factors include an excessive magnesium load prior to administration, such as in patients who may take large quantities of antacids, laxatives, cathartics, or who receive parenteral administration of magnesium.

Over the last century, there are multiple published reports of patient death caused by magnesium toxicity following Epsom salts enema in the literature and as such safer treatments for constipation and abdominal pain should be used.

Contributory Factors

1. The use of magnesium sulfate (Epsom salts) is a seemingly benign therapy, as it is a naturally occurring product, is available over-the-counter, and has been used for many centuries in our population to relieve gastrointestinal symptoms including abdominal pain and chronic constipation.
2. There was found to be little knowledge among care providers about the magnesium content in the Epsom salt component of the 2-4-6 enema.
3. In patients with normal renal function, most extra magnesium ingested can be completely and easily eliminated. However, the potential exists for serious or fatal complications in patients with renal impairment or with a high baseline magnesium load.

Patient safety alerts may be issued by the Ministry of Health following the review of at least one critical incident reported to the Ministry. A critical incident is defined as a serious adverse health event including, but not limited to, the actual or potential loss of life, limb or function related to a health service provided by, or a program operated by, a regional health authority, Saskatchewan Cancer Agency or health care organization.

The purpose of a patient safety alert is to recommend actions that will improve the safety of patients who may be cared for under similar circumstances. Recommendations are intended to support the development of best practices and to act as a framework for improvement and can be adapted to fit the needs of the health service organization. When possible, policies or initiatives that have been developed by RHAs or the Saskatchewan Cancer Agency will be shared, to encourage adoption of similar policies or actions.



Case Report

Iatrogenic hypermagnesemia following Epsom salt enema

Michael R. Prystajecy^a, Sarah Parent^a, Habib ur Rehman^{b,*}^a College of Medicine, University of Saskatchewan, Saskatoon, Canada^b Regina Qu'Appelle Health Region, Regina, Canada

Received 27 October 2014; revised 24 April 2015; accepted 18 June 2015

Available online 29 August 2015

Abstract

Constipation is a common problem in the older population. Among other treatment modalities, Epsom salt enema has been used in emergency rooms. Since Epsom salts are 100% magnesium sulfate and excreted wholly through the kidneys, hypermagnesemia may result from their use, particularly in patients with impaired renal function. A case of fatal iatrogenic hypermagnesemia resulting from the administration of an Epsom salt enema is presented here. We suggest that magnesium-containing enemas should be avoided in patients with impaired renal function. Copyright © 2015, Taiwan Society of Emergency Medicine. Published by Elsevier Taiwan LLC. All rights reserved.

Keywords: enema; Epsom salts; hypermagnesemia; iatrogenic; renal failure

1. Introduction

Hypermagnesemia is a rare but potentially fatal condition if unrecognized. The majority of reported cases of hypermagnesemia are iatrogenic, arising from the administration of magnesium-containing laxatives or antacids,^{1–4} magnesium-containing enemas,^{5,6} or intravenous magnesium sulfate.⁷ Magnesium toxicity presents with nonspecific signs and symptoms⁸ and is therefore difficult to diagnose based on clinical findings. We present a case of iatrogenic hypermagnesemia resulting from the administration of an Epsom salt enema.

2. Case Report

An 85-year-old woman presented to the emergency department with a 3-day history of constipation and diffuse abdominal pain. Her past medical history was significant for amyloid light chain amyloidosis, hemodialysis-dependent end-

stage renal disease, gastric angiodysplasia, and anemia. On presentation, her blood pressure was 147/69 mmHg, and all other vital signs were normal. Her cardiac, respiratory, and abdominal examinations were unremarkable. Complete blood count revealed a hemoglobin level of 99 g/L (120–160 g/L), with a normal white blood cell and platelets count; prothrombin and partial thromboplastin times were normal; and urea was 18.6 mmol/L (3.0–7.1 mmol/L), creatinine 972 μmol/L (60–130 μmol/L), sodium 133 mmol/L (135–145 mmol/L), potassium 4.6 mmol/L (3.5–5.0 mmol/L), chloride 99 mmol/L (98–110 mmol/L), calcium 2.36 mmol/L (2.14–2.66 mmol/L), phosphate 1.79 mmol/L (0.89–1.55 mmol/L), and magnesium 0.81 mmol/L (0.70–1.10 mmol/L). An abdominal X-ray revealed dilated small bowel loops and a minimally distended colon. No air–fluid levels or free air was seen.

Shortly after presentation, an enema containing water, glycerin, and 28 g of Epsom salts (approximately 3 g of elemental magnesium) was administered, with no evacuation of stool. Over the subsequent 7 hours, the patient developed worsening abdominal distension and bowel sounds became absent. A large ecchymosis appeared on the right side of the patient's face, accompanied by the onset of rectal and vaginal bleeding. The patient's neurologic status deteriorated, with

* Corresponding author. Regina Qu'Appelle Health Region, Suite 100, 2550 12th Avenue, Regina SK S4P 3X1, Canada.

E-mail address: habib31@sasktel.net (H. Rehman).

progressive skeletal muscle paralysis, loss of deep tendon reflexes, and inability to speak. Breathing became shallow, and oxygen requirements increased to 10 L on a nonrebreather mask. Rectal temperature fell to a nadir of 33.8°C (Figure 1). Electrocardiography was performed, which showed first-degree atrioventricular block (PR interval 218 milliseconds) and a prolonged QRS interval (118 milliseconds). Piperacillin–tazobactam was administered due to concern of sepsis, followed by cryoprecipitate and platelets in an attempt to correct the bleeding. Blood work drawn 2 hours after the enema revealed the following: a calcium level of 2.94 mmol/L, a phosphate level of 1.72 mmol/L, and a magnesium level that

exceeded the detectable range of the assay (>7.8 mmol/L). Unfortunately, the treating team of physicians was unaware of these results.

Seven hours after the administration of the magnesium-containing enema, the consulting internal medicine team noted the patient's elevated magnesium level. Repeat blood work confirmed the diagnosis of hypermagnesemia (>7.8 mmol/L), and revealed normal partial thromboplastin time (PTT) and International normalised ratio (INR), hemoglobin level 89 g/L, white blood cell count $10.7 \times 10^9/L$, and platelet count $139 \times 10^9/L$. The patient was sent urgently for dialysis. Post dialysis, the patient's oral temperature

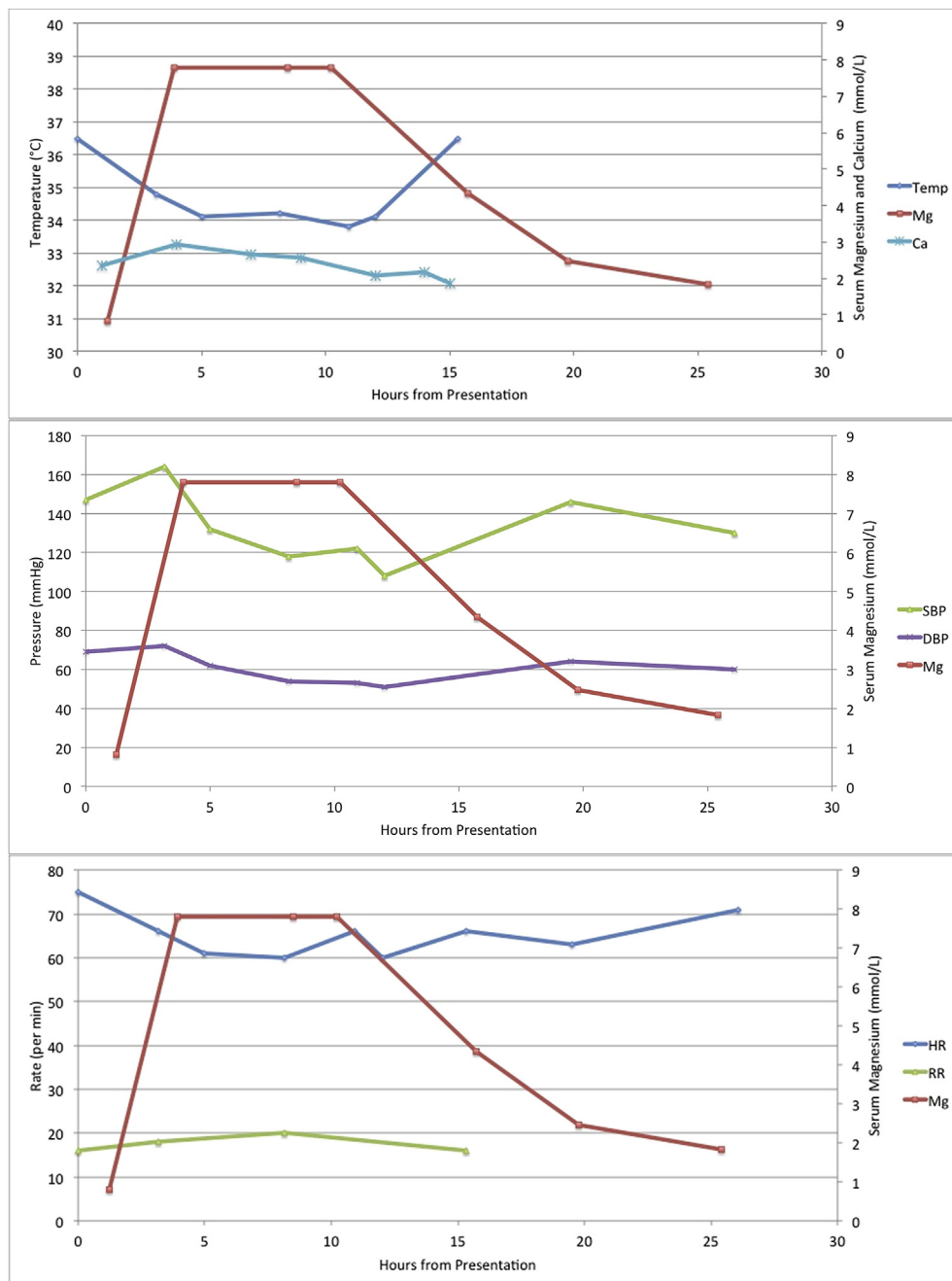


Figure 1. Vital signs in relation to magnesium levels. DBP = diastolic blood pressure; HR = heart rate; RR = respiratory rate; SBP = systolic blood pressure.

normalized and oxygen requirements declined to 3 L by nasal prongs. She was alert and speaking, patellar reflexes were reduced bilaterally, and strength had improved throughout. Repeat electrocardiography revealed normal sinus rhythm, a PR interval of 178 milliseconds, and a QRS interval of 84 milliseconds. The postdialysis serum magnesium level was 4.35 mmol/L, and a second hemodialysis treatment on the same day reduced the magnesium concentration to 2.47 mmol/L. The patient received hemodialysis every other day for the management of her end-stage renal disease, and serum magnesium levels gradually normalized. However, the patient continued to experience fatigue, poor appetite, and muscle weakness. On Day 9 post admission, the patient declined further hemodialysis and care was transferred to a palliative care physician. She died peacefully.

3. Discussion

Renal excretion is the sole route of magnesium elimination⁸; therefore, hypermagnesemia most frequently occurs in the context of renal impairment. However, magnesium toxicity has also been reported in patients with normal renal function,⁹ and impaired gastrointestinal motility has been cited as an additional risk factor.^{4,10} In the present case, end-stage renal disease and impaired intestinal motility were predisposing conditions for the development of magnesium toxicity. The patient received approximately 28 g of Epsom salts, which are 100% magnesium sulfate. This is equivalent to 2.8 g of elemental magnesium, a considerable amount given that the recommended daily allowance for an adult is 300–400 mg per day.⁸

Hypermagnesemia presents with nonspecific signs and symptoms.⁸ Neurologic effects include lethargy, loss of deep tendon reflexes, skeletal muscle paralysis, and coma. Cardio-respiratory effects are bradycardia, hypotension, first-degree atrioventricular block, QT interval prolongation, respiratory depression, and ultimately cardiopulmonary arrest. Hypermagnesemia has also been associated with paralytic ileus.² The toxic effects of supraphysiologic magnesium levels are due to antagonization of calcium-dependent acetylcholine release at neuromuscular junctions and calcium-channel blocking effects on cardiac myocytes.^{8,11} With the exception of hypotension, bradycardia, and cardiopulmonary collapse, the patient in the present case report displayed all the aforementioned features of hypermagnesemia.

Several treatment options are available to correct hypermagnesemia. Since magnesium competitively binds to calcium channels and hence acts as a calcium-channel blocker, administration of intravenous calcium can reverse cardiac arrhythmia, respiratory depression, and hypotension. Adequate hydration and use of diuretics may help eliminate excess magnesium through diuresis. Hemodialysis can be lifesaving in cases of severe toxicity and in patients not responding to other less invasive measures.

Several aspects of the patient's presentation are noteworthy. First, the patient became hypothermic shortly after the administration of the magnesium-sulfate enema. Hypothermia associated with hypermagnesemia has been described

previously^{1,3}; however, it is not widely recognized as a clinical manifestation of magnesium toxicity. The onset of hypermagnesemia in the present report was associated with a concomitant rise in serum calcium concentration, which has been reported only twice previously.^{5,12} This is likely because of the exchange of calcium at the bone surfaces with magnesium in the circulation.¹³ In contrast, hypermagnesemia is more frequently associated with hypocalcaemia,^{1,6,9} an effect that is mediated through depression of parathyroid hormone levels due to hypermagnesemia.¹⁴ Finally, the patient developed significant bruising and bleeding following the onset of magnesium toxicity. Although uremia and amyloidosis would have predisposed the patient to bleeding due to platelet and factor X dysfunction, it is possible that hypermagnesemia may have been a precipitating factor. This is supported by the experimental observation that magnesium inhibits platelet aggregation both *in vitro* and *in vivo*.^{15,16}

3.1. Learning points

- (1) Iatrogenic hypermagnesemia may be associated with hypothermia, elevated serum calcium levels, and bleeding diathesis. Hypothermia and hypercalcemia are rare sequelae of magnesium toxicity.
- (2) This case provides additional evidence for avoiding magnesium-containing enemas in patients with impaired renal function or gastrointestinal motility disorders.
- (3) Physicians should consider tap water or polyethylene glycol-containing enemas as alternatives in these clinical contexts.

Conflicts of interest

None of the authors have any financial conflicts of interest to declare.

References

1. Gerard SK, Hernandez C, Khayam-Bashi H. Extreme hypermagnesemia caused by an overdose of magnesium-containing cathartics. *Ann Emerg Med.* 1988;17:728–731.
2. Golzarian J, Scott Jr HW, Richards WO. Hypermagnesemia-induced paralytic ileus. *Digest Dis Sci.* 1994;39:1138–1142.
3. Birrer RB, Shallash AJ, Totten V. Hypermagnesemia-induced fatality following Epsom salt gargles(1). *J Emerg Med.* 2002;22:185–188.
4. Kontani M, Hara A, Ohta S, Ikeda T. Hypermagnesemia induced by massive cathartic ingestion in an elderly woman without pre-existing renal dysfunction. *Intern Med.* 2005;44:448–452.
5. Collinson PO, Burroughs AK. Severe hypermagnesaemia due to magnesium sulphate enemas in patients with hepatic coma. *Br Med J Clin Res Ed.* 1986;293:1013–1014.
6. Tofil NM, Benner KW, Winkler MK. Fatal hypermagnesemia caused by an Epsom salt enema: a case illustration. *South Med J.* 2005;98:253–256.
7. Vissers RJ, Purssell R. Iatrogenic magnesium overdose: two case reports. *J Emerg Med.* 1996;14:187–191.
8. Jähnen-Dechent W, Ketteler M. Magnesium basics. *CKJ Clin Kidney J.* 2012;5(Suppl. 1):i3–i14.
9. Kutsal E, Aydemir C, Eldes N, et al. Severe hypermagnesemia as a result of excessive cathartic ingestion in a child without renal failure. *Pediatr Emerg Care.* 2007;23:570–572.

10. Brown AT, Campbell WA. Hazards of hypertonic magnesium enema therapy. *Arch Dis Child*. 1978;53:920.
11. Agus ZS, Morad M. Modulation of cardiac ion channels by magnesium. *Annu Rev Physiol*. 1991;53:299–307.
12. Ashton MR, Sutton D, Nielsen M. Severe magnesium toxicity after magnesium sulphate enema in a chronically constipated child. *BMJ*. 1990;300:541.
13. Neuman MW, Imai K, Kawase T, Saito S. The calcium-buffering phase of bone mineral: some clues to its form and formation. *J Bone Miner Res*. 1987;2:171–181.
14. Cholest IN, Steinberg SF, Tropper PJ, Fox HE, Segre GV, Bilezikian JP. The influence of hypermagnesemia on serum calcium and parathyroid hormone levels in human subjects. *N Engl J Med*. 1984;310:1221–1225.
15. Canton R, Manzanares J, Alvarez E, Zaragoza F. *In vitro* and *in vivo* antiaggregant effects of magnesium halogenates. *Thromb Haemost*. 1987;58:957–959.
16. Paolisso G, Tirelli A, Coppola L, et al. Magnesium administration reduces platelet hyperaggregability in NIDDM. *Diabetes Care*. 1989;12:167–168.